



# **Histopathological Effect of Aqua Fix Supplementation on the Skeletal Muscle and Liver of *Labeo rohita* (Hamilton, 1822) during Immunomodulation and Aeromoniasis**

**Ankamma, N. <sup>a\*</sup> and Viveka Vardhani, V. <sup>b</sup>**

<sup>a</sup> Department of Zoology, Y.A. Government Degree College for Women, Chirala, Bapatla Dt-523157 (A.P.), India.

<sup>b</sup> Department of Zoology and Aquaculture, Acharya Nagarjuna University, Nagarjunanagar-522 510 (A.P.), India.

## **Authors' contributions**

*This work was carried out in collaboration between both authors. Both authors read and approved the final manuscript.*

## **Article Information**

DOI: <https://doi.org/10.9734/ajfar/2025/v27i1867>

## **Open Peer Review History:**

This journal follows the Advanced Open Peer Review policy. Identity of the Reviewers, Editor(s) and additional Reviewers, peer review comments, different versions of the manuscript, comments of the editors, etc are available here:

<https://www.sdiarticle5.com/review-history/129546>

**Original Research Article**

**Received: 03/11/2024**

**Accepted: 08/01/2025**

**Published: 14/01/2025**

## **ABSTRACT**

The impact of oral feeding diet (supplement) Aqua Fix was studied on the histopathological changes in skeletal muscles and liver of *L. rohita* during immunomodulation and aeromoniasis. Three groups (D,E,F) of six months old fish were employed; groups D and E were treated with Aqua Fix for 4 days, on day 5 fish of group E and F were infected with *Aeromonas hydrophila* @

\*Corresponding author: Email: [ankamma.zoology@gmail.com](mailto:ankamma.zoology@gmail.com);

10<sup>6</sup>CFU/fish(fish of group F were fed with normal diet for 4 days).Controls (group G) were untreated and uninfected. Histological examination of the skeletal muscle and liver tissues were carried out on selected days of experimentation (day 1 and day 4 of experiment). The stained sections were observed under microscope and histological changes were noted. Immunostimulated fish (group D) showed normal arrangement of muscle fibers and muscle bundles compared to other groups (E and F) of fish. Both the muscle fibers and muscle bundles were healthy as in controls (Group G). In infected group (untreated with Aqua Fix, group F), fragmentation of muscle fibers was noticed along with sarcoplasmic debris. Dermal lesions and moderate edema is noticed in necrotic muscle fibers. Liver in immunostimulated fish showed large, polygonal hepatocytes with distinct, round nuclei. Hepatic central vein and sinusoids were clearly visible. By day 1 of infection, liver exhibited necrosis of hepatocytes, pycnosis of hepatocyte nuclei, granulation and vacuolisation (group F). Dilation of hepatic vein and sinusoids were observed. Necrotic foci and haemorrhages were evident in the capillaries of liver and occurred more severely in group F compared to group E (treated with Aqua Fix and infected). The fish (group E) which received immunostimulant and infection showed moderate effect on liver suggesting that Aqua Fix supplementation ameliorate the ill effects of *A. hydrophila*, showing the positive influence of herbal immunostimulant i.e, Aqua Fix in fresh water fish.

**Keywords:** Skeletal muscle; liver; immunostimulant; *Aeromonas hydrophila*; *Labeo rohita*.

## 1. INTRODUCTION

*Aeromonas hydrophila* has been reported to cause dropsy, hemorrhagic septicemia, ulcers, skin lesions, bleeding of internal organs and tail and fin rot (Rahman et al; 2001). *L. rohita* infected with *A. hydrophila* showed much variation in the haematology, enzyme activities and tissue sections revealed dermal edema, muscular degeneration and necrosis of liver, glomeruli and renal tubules of kidney (Manoj et al; 2010). Marked histopathological changes were found in liver and kidney of *Heteropneustes fossilis* infected with *A. hydrophila* (Islam et al; 2011). Also in estuarine cat fish and *H. fossilis* (Alagappan et al; 2009; Islam et al; 2013), cutaneous lesions, hyperemia of abdominal organs and internal organs pathological lesions (Rasmussen-Iver et al; 2016; Abdelhamed et al; 2017). *A. hydrophila* infection has been found in a wide variety of hosts (Huizinga et al., 1979; Soltani et al., 1998); in *C. carpio* (Vivas et al., 2004) and channel catfish *Ictalurus punctatus* (Galindo et al., 2004). *A. hydrophila* has been reported to cause red fin disease in cultured eel, *Anguilla japonica* (Hoshima, 1962), red sore disease in large mouth bass, *Micropterus salmonides* (Huizinga et al., 1979) and haemorrhagic septicemia in *C. carpio* (Miyazaki et al., 1985), catfish larvae, *Silurus asotus* (Kuge et al., 1992) and in cyprinid fish (Zhang et al., 2014). Aeromoniasis in large mouth bass, *M. salmonoides*, lead to necrosis in liver, kidney and heart. Destruction of hepatocytes and affinity of these bacteria to the liver were found (Datta Ray

and Homechaudhuri, 2014). Pal et al., (2015) reported that *L. rohita* after *A. hydrophila* infection exhibited hepatic damage characterized by granulomatous inflammation, aggregation of melanomacrophage centres (MMC) and rupturing and cytolysis of hepatocytes leading to distortion of hepatic chords.

Aeromoniasis and its causative pathogens can be detected in fish in various ways including: analysis of biochemical parameters (Gabriel et al. 2015, Ukwe 2021), histopathological and haematological assessment (Ukwe et al. 2021, Ukwe and Deekae 2022). Ipomoea batatas (sweet potato) leaf possess significant nutrients and phytochemicals that can enhance productivity in aquaculture (Ukwe and Deekae 2024). The use of herbs as feed supplements can be very beneficial in improving fish growth and feed efficiency, as well as contributing to better disease prevention (Reverter et al. 2021), thereby enhancing sustainability of the aquaculture value chain.

Intramuscular injection of *A. hydrophila* caused sloughing of scales and ulcerative dermatitis associated with edema and dermal necrosis exposing the underlying muscles in Goldfish *Carassius aurat* (Harikrishnan et al. 2009).

Aqua Fix is a highly specialized pure herbal preparation consists of alkaloids of *Azadirachta indica*, *Ocimum sanctum*, *Phyllanthus niruri* and *Withania somnifera* having strong antimicrobial and immunity enhancing properties.

## 2. MATERIALS AND METHODS

*L. rohita*, an Indian major carp of approximately 6 months (12-15 g) old were collected from local fish farm, Singh farms, Kuchipudi (V), Amrataluru (M), Guntur (D), Andhra Pradesh, India. In the laboratory fish were kept in the plastic tubs and acclimatized for 7 days. Water quality parameters were within optimum range and the water quality was regularly monitored. Fish were fed with commercially available pellet food. Two-third of the water was renewed every day using de-chlorinated ground water to maintain good water quality. Three experimental groups of six month old *L. rohita* (12-15 g) were selected for the experimentation. Groups, D(treated with Aqua Fix), E (treated with Aqua Fix and infected with *A. hydrophila*), F (untreated with Aqua Fix but infected with *A. hydrophila*) and one control group, G (untreated and uninfected) of fish (35 in each group) were maintained in optimum conditions. Fish of group D and E fed with a diet supplemented with Aqua Fix (50mg/100 g of feed) for 4 days; on the 5<sup>th</sup> day fish of group E and F were infected intraperitoneally with *A. hydrophila* ( $10^{-6}$  CFU/fish). Fish of groups F and G were fed with normal diet (without Aqua Fix) during the entire experimental period.

### 2.1 Bacterial Culture

The bacterial strain used in this study, *Aeromonas hydrophila* was supplemented from State Institute of Fisheries Technology (SIFT), Kakinada, (A.P.), India. This parent culture was subsequently revived by nutrient broth and transferred the culture to a nutrient agar medium. Culture and preparation of isolated bacterial colonies were made under aseptic conditions following the method of Pelczar (1993).

### 2.2 Histopathology

Histological examination of the skeletal muscle and liver tissues were carried out on selected days of experimentation (day 1 and day 4 of experiment). Isolated muscle and liver tissues of control and experimental fish were gently rinsed with normal physiological saline (0.9% NaCl) to remove blood and debris adhering to the tissues and were fixed in 10% formalin. After dehydrating to a graded series of alcohols, the tissues were cleared in absolute methyl alcohol and xylene, and embedded in paraffin wax. Sections were cut at 5  $\mu$  thickness and stained with haematoxylin and eosin (H&E). After dehydration and clearing, sections were mounted with DPX. The stained

sections were observed under microscope and histological changes were noted.

## 3. RESULTS AND DISCUSSION

The tissue sections of muscles and liver of 6 months old *L. rohita* displayed marked histological / pathological changes during bacterial infection (groups E– treated with Aqua Fix + infected; F– infected). The fish which were fed with Aqua Fix (groups D) and control (group G) showed normal architecture in the muscles and liver throughout the experiments.

### Skeletal Muscles:

#### Microscopic examination:

##### On day 1 of experiment:

Group G (control, untreated with Aqua Fix and infection) (Fig. 1, G1):

Histological structure of muscle showed normal arrangement of muscle fibers (myofibrils) and muscle bundles on day 1 of experiment.

Groups D (treated with Aqua Fix), E (treated with Aqua Fix and infected with *A. hydrophila*) and F (infected with *A. hydrophila*) (Fig. 1; D1, E1, F1)

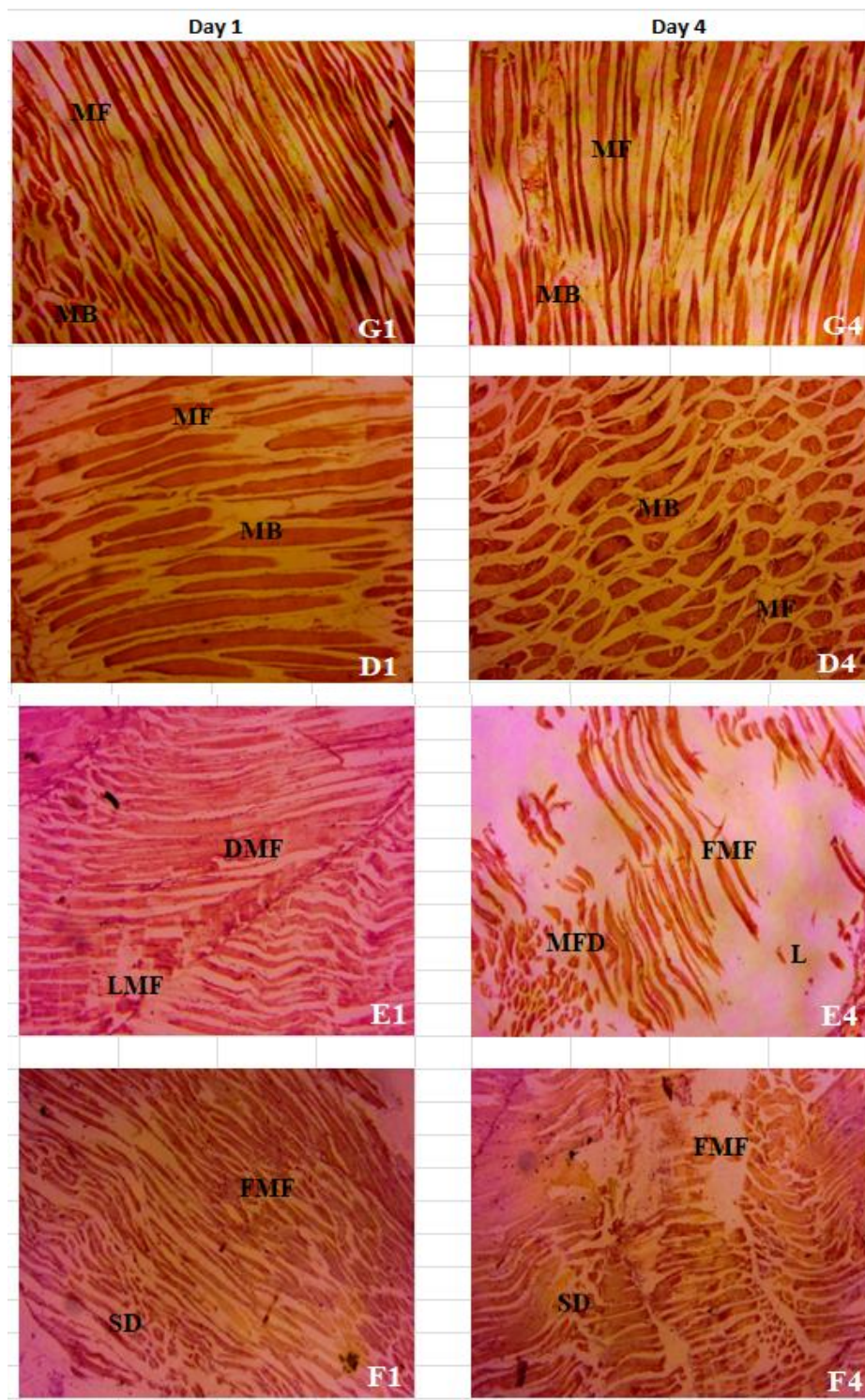
Immunostimulated fish (group D) showed normal arrangement of muscle fibers and muscle bundles compared to other groups (E and F) of fish. Both the muscle fibers and muscle bundles were healthy as in controls (Group G) (Fig.1 G1). In the immunostimulated and infected fish (group E), there was slight derangement of muscle fibers. Also, muscle fibers slightly lost their elongation and appeared slightly curved. Sarcoplasmic debris appeared at certain places. Hypertrophy is seen in muscle bundles (Fig. 1, E1). In infected group (untreated with Aqua Fix, group F), fragmentation of muscle fibers was noticed along with sarcoplasmic debris. Dermal lesions and moderate edema is noticed in necrotic muscle fibers (Angka 1990).

##### On day 4 of experiment:

Group G (control, untreated with Aqua Fix and infection) (Fig. 1, G4):

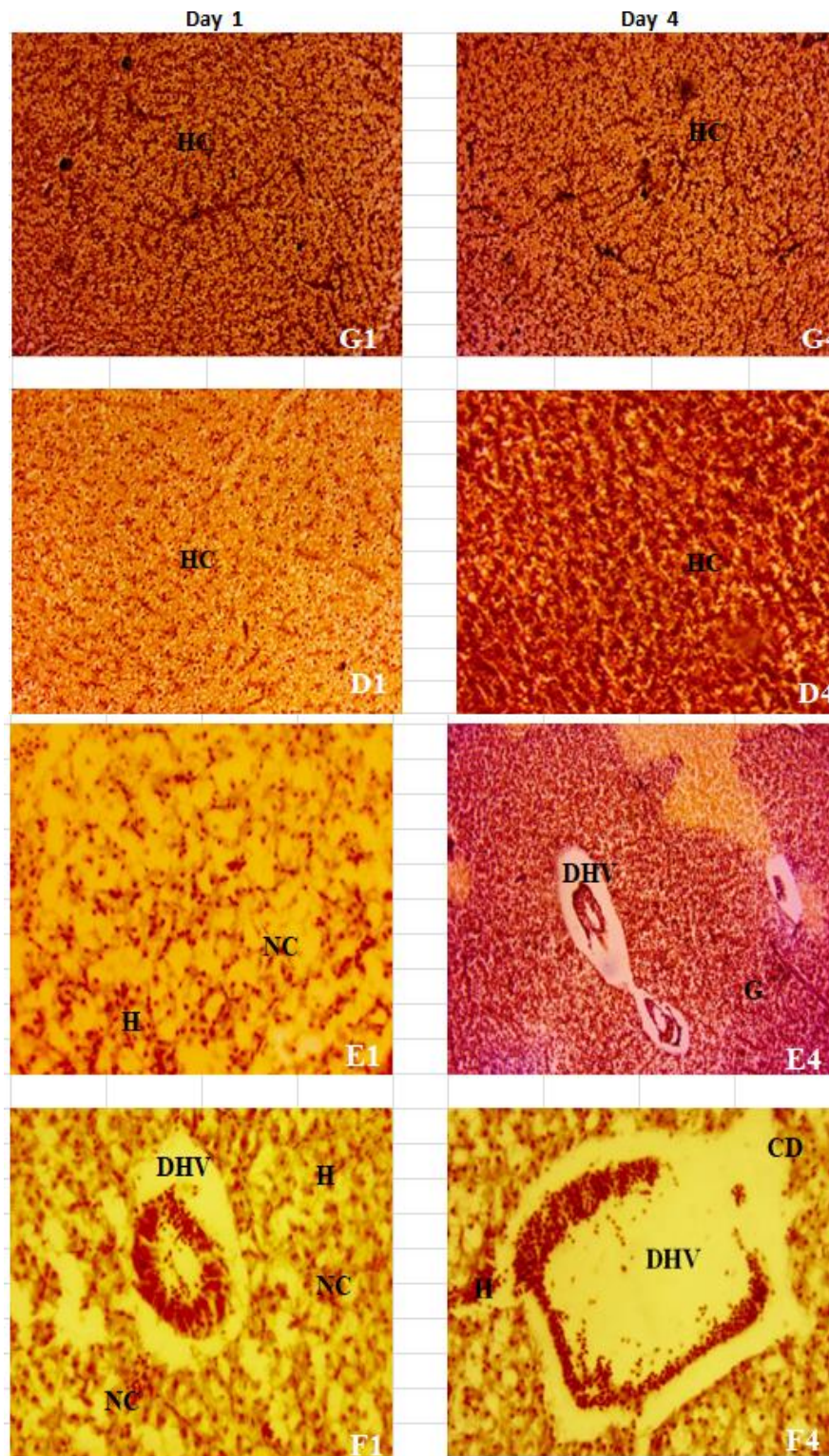
Histological structure of muscle showed normal arrangement of muscle fibers (myofibrils) and muscle bundles on day 4 of experiment.

Groups D (treated with Aqua Fix), E (treated with Aqua Fix and infected with *A. hydrophila*) and F (infected with *A. hydrophila*) (Fig. 1; D4, E4, F4)



**Fig. 1.** Showing the section of skeletal muscles of *L. rohita* (6 months old) from group G (control, untreated with Aqua Fix and uninfected), group D (Aqua Fix treated @ 50mg/100g of feed), group E (treated with Aqua Fix @ 50mg/100g of feed+ infected with *A. hydrophila* @  $10^{-6}$  CFU/fish) and group F (infected with *A. hydrophila* @  $10^{-6}$  CFU/fish) on day 1 and 4 of experimental period. Abbreviations: MF – Muscle fiber; MB – Muscle bundle; DMF – Derangement of muscle fibers; LMF – Loss of muscle fibers; FMF – Fragmentation of muscle fibers; SD – Sarcoplasmic debris; MFD – Muscle fiber degeneration; L – Lacuna





**Fig. 2.** Showing the section of liver of *L. rohita* (6 months old) from group G (control, untreated with Aqua Fix and uninfected), group D (Aqua Fix treated @ 50mg/100g of feed), group E (treated with Aqua Fix @ 50mg/100g of feed+ infected with *A. hydrophila* @  $10^{-6}$  CFU/fish) and group F (infected with *A. hydrophila* @  $10^{-6}$  CFU/fish) on day 1 and 4 of experimental period. Abbreviations: HC – Hepatocytes; H – Haemorrhages; NC – Necrotic foci; DHV – Dilatation of hepatic vein; G – Granulation; CD – Cell debris

Histological structure of muscles in immunostimulated fish (group D) was characterised by the presence of normal arrangement of healthy muscle fibers and muscle bundles (Fig. 1, D4). In Aqua Fix treated and infected fish (Group E), the muscle bundles and muscle fibers were markedly fragmented; the fragments of muscle fibers accumulated at certain places. Lacunae were clearly visible in musculature due to muscular degeneration (Fig. 1, E4). Marked oedema, vacuolation, necrosis and dermal lesions were observed in the muscle tissue of infected fish (group F; Fig. 1, F4). Derangement and fragmentation of muscle fibers, cloudy appearance of muscle fibers and scattered sarcoplasmic debris were also noticed.

#### **Liver:**

##### **Microscopic examination:**

Hepatocytes are large, polygonal in shape with almost centrally placed nuclei. Blood sinusoids were clearly evident.

##### **On day 1 of experiment:**

Group G (control, untreated and uninfected) (Fig. 2, G1)

Large, polygonal hepatocytes. Nuclei of hepatocytes are distinctly round and almost centrally placed with exhibited prominent central vein, sinusoids were clearly observed.

Groups D (treated with Aqua Fix), E (treated with Aqua Fix and infected with *A. hydrophila*) and F (infected with *A. hydrophila*) (Fig. 2, D1, E1 F1 respectively):

Histological analysis of the liver in group E, fish showed large, polygonal hepatocytes with distinct, round nuclei. Hepatic central vein and sinusoids were clearly visible (Fig. 2, D1), liver tissue exhibited haemorrhagic spots, vacuolisation and granulation. Slight disruption appeared in hepatocytes (Fig. 2, E1). By day 1 of infection, liver exhibited necrosis of hepatocytes, pycnosis of hepatocyte nuclei, granulation and vacuolisation (group F; Fig. 2, F1). Dilation of hepatic vein and sinusoids were observed, necrotic foci and haemorrhages were evident in the capillaries of liver and occurred more severely compared to group E (treated with Aqua Fix and infected).

##### **On day 4 of experiment:**

Group G (control, untreated and uninfected) (Fig. 2, G4)

Large, polygonal hepatocytes, nuclei of hepatocytes are distinctly round and almost centrally placed. Hepatocytes exhibited prominent central vein, sinusoids were clearly observed.

Groups D (treated with Aqua Fix), E (treated with Aqua Fix and infected with *A. hydrophila*) and F (infected with *A. hydrophila*) (Fig. 2, D4, E4, F4)

It is noticed a continuous mass of hepatocytes which are large, polygonal with distinct nucleie (Fig. 2, D4). The hepatic tissue (of both groups D & E) showed mild vacolisation, granulation and haemorrhages, where mild dilation of veins and sinusoids were evident (Fig. 2, E4). Necrotic hepatocytes, pycnosis, vacuolization, cell debris, haemorrhages and necrotic foci were found in infected fish (group F). Veins and sinusoids were markedly dilated (Fig. 2, F4).

## **4. CONCLUSION**

The fish (group E) which received immunostimulant and infection showed moderate effect on liver suggesting that Aqua Fix supplementation ameliorate the ill effects of *A. hydrophila*, showing the positive influence of immunostimulants in freshwater fish which in turn retains the normal histology to certain extent compared to other groups. So herbs and herbal products have proven to be good solutions and replacement for synthetic drugs in the practice of aquaculture as they are eco-friendly. Aqua fix seems to possess the potentials of maintaining normal biochemical activities and safe guard fish liver against *A. hydrophila*. This study shows the significant variability in response to infection and immunomodulation in various tissues.

## **DISCLAIMER (ARTIFICIAL INTELLIGENCE)**

Author(s) hereby declare that NO generative AI technologies such as Large Language Models (ChatGPT, COPILOT, etc.) and text-to-image generators have been used during the writing or editing of this manuscript.

## **ACKNOWLEDGEMENTS**

One of the authors (ANKAMMA. N.) is thankful to UGC for providing financial support in the form of FDP.

## **COMPETING INTERESTS**

Authors have declared that no competing interests exist.

## REFERENCES

- Abdelhamed. et.al; 2017, Characterization of Histopathological and Ultrastructural Changes in Channel Catfish Experimentally Infected with Virulent *Aeromonas hydrophila*, Front microbiol 15;8:1519. doi: 10.3389/fmicb.2017.01519
- Alagappan K. M., Deivasigamani B., Kumaran S., Sakthivel M. (2009). Histopathological alterations in estuarine catfish due to *Aeromonas hydrophila* infection. *World J. Fish Mar. Sci.* 1: 185–189.
- Angka, S.L. 1990. The pathology of the walking catfish, *Clarias batrachus* (L.) infected intraperitoneally with *A. hydrophila*. *Asian Fish. Sci.* 3: 341-351.
- Candan, A.A. 1990. A study on the histopathology of *A. hydrophila* infections of rainbow trout (*Salmo gairdneri* R.) kept under experimental conditions and the effect of choramphenicol. *J. Aquat. Prod.* 4: 5-20
- Datta Ray, S. and Homechaudhuri, S. 2014. Morphological and functional characterization of hepatic cells in Indian Major Carp (*Cirrhinus mrigala*) against *A. hydrophila* infection. *J. Environ. Biol.* 35: 253-258
- Gabriel, N.N., Quiang, J., Ma, X.Y., He, J., Xu, P. and Liu, K. (2015) Dietary Aloe vera improve plasma lipid profile, antioxidant, and hepatoprotective enzyme activities in tilapia (*Oreochromis niloticus*) after *Streptococcus iniae* challenge. *Fish physiology and Biochemistry.*; 4:1321 – 1332.
- Galindo, C.L., Fadl, A.A., Sha, J., Gutierrez, Jr. C., Popov, V.L., Boldogh, I., Agarwal, B.B. and Chopra, A.K. 2004. *Aeromonas hydrophila* cytotoxic enterotoxin activates mitogen-activated protein kinases and induces apoptosis in murine macrophages and human intestinal epithelial cells. *J. Biol. Chem.* 279: 37597-37612.
- Gupta, S.K., Pal, A.K. Sahu, N.P., Dalvi, R., Kumar, V. and Mukherjee, S.C. 2008. Microbial levan in the diet of *Labeo rohita* Hamilton juveniles effect on non-specific immunity and histopathological changes after challenge with *Aeromonas hydrophila*. *J. Fish Dis.* 31: 649-657.
- Harikrishnan, R. and Balasundaram, C. 2005. Modern trends in *Aeromonas hydrophila* disease management with fish. *Rev. Fish Sci.* 13: 281-320.
- Harikrishnan, R., Balasundaram, C., Young-Gunman, Man-Chul Kini, Ju-Sang Kim and Moon-Soo Heo. 2009. Use of herbal concoction in the therapy of goldfish (*Carassius auratus*) infected with *Aeromonas hydrophila*. *Bull. Vet. Inst. Pulawy.* 53: 27-36.
- Hassan, M.A., Rashid, M.M., Islam, M.A., Mostafa, K. and Islam, M.T. 2008. Histopathological studies of EUS affected shing *Heteropneustes fossilis* from a fish farm of Mymensingh. *Bangladesh J. Fish. Res.*, 12(1): 12-36.
- Hossain, F.M., Rashid, M.M. and Sayed, M.A. 2011. Experimental infection of indigenous climbing perch. *Anabas testudineus* with *Aeromonas hydrophila* bacteria. *Progress. Agric.* 22(1&2): 105-114.
- Huisinga, H.W., Esch, G.W. and Hazen, T.C. 1979. Histopathology of red-sore disease (*Aeromonas hydrophila*) in naturally and experimentally infected large mouth bass, *Micropterus salmoides* (Lacepeda). *J. Fish Dis.* 2: 263-277.
- Islam M., Mostafa K., Rashid M. (2013). Histopathological studies of experimentally infected shing, *Heteropneustes fossilis* with *Aeromonas hydrophila* bacteria. *Prog. Agric.* 19: 89–96. 10.3329/pa.v19i1.17359
- Islam, M.T., Rashid, M.M. and Mostafa, K. 2008. Histopathological studies of experimentally infected shing, *Heteropneustes fossilis* with *Aeromonas hydrophila* bacteria. *Progress. Agric.* 19(1): 89-96.
- Kuge, T., Takahashi, K., Barcs. I., and Hayashi, F. 1992. *Aeromonas hydrophila*, a causative agent of mass mortality in cultured Japanese catfish larvae (*Silurus asotus*). *Fish Pathol.* 27: 57–62
- Manoj, C.K., Mohankumaran, Nair, C., Patel, M.B. and Salin, K.R. 2010. Haematobiochemical and histopathological changes in *Labeo rohita* infected with *Aeromonas hydrophila* by immersion challenge. *Fishery Technol.* 47(2): 151-160.
- Miyazaki, T. and Jo, Y. 1985. A histopathological study of motile aeromonad disease in ayu. *Fish Pathol.* 20: 55-59.
- Pal, S., Ray, S.D. and Homechaudhuri, S. 2015. Evaluation of *in vivo* non-specific immunity and oxidative stress in *Labeo rohita* (Hamilton, 1822) infected with *Aeromonas hydrophila* as biomarker for early diagnosis. *Int. J. Fish. Aqua. Stu.* 3(1): 116-124.

- Pelczar, M.J. Jr., Chan, E.C.S. and Noel, R.K. 1993. Characterization of microorganisms. Microbiology concepts and applications. 5<sup>th</sup> ed. Tata McGraw Hill Publishing Co. Ltd., pp. 81-83 (Robert Koch, 1883).
- Rahman, M.H., Suzuki, S. and Kawai, K. 2001. The effect of temperature on *Aeromonas hydrophila* infection in gold fish, *Carassius auratus*, J. Appl. Ichthyol. 17: 282-285.
- Rairakhwada, D., Pal, A.K., Bathena, Z.P., Sahu, N.P., Jha, A. and Mukherjee, S.C. 2006. Dietary microbial levan enhances cellular non-specific immunity and survival of common carp (*Cyprinus carpio*) juveniles. Fish & Shellfish Immunol. 22: 477-486.
- Rasmussen-Ivey C. R., Hossain M. J., Odom S. E., Terhune J. S., Hemstreet W. G., Shoemaker C. A., et al. 2016, Classification of a hypervirulent *Aeromonas hydrophila* pathotype responsible for epidemic outbreaks in warm-water fishes. *Front. Microbiol.* 7: 1615 10.3389/fmicb.2016.01615
- Reverter, Miriam, Nathalie Tapissier-Bontemps, Samira Sarter, Pierre Sasal, and Domenico Caruso. 2021. "Moving towards More Sustainable Aquaculture Practices: A Meta-Analysis on the Potential of Plant-Enriched Diets to Improve Fish Growth, Immunity and Disease Resistance." *Reviews in Aquaculture* 13 (1): 537–55.
- Selvaraj, V., Sampat, K. and Sekhar, V. 2005. Administration of yeast glucan enhances survival and some non-specific and specific immune parameters in carp (*Cyprinus carpio*) infected with *Aeromonas hydrophila*. Fish & Shellfish. Immunol. 19: 293-306.
- Soltani, N., Mirzargar, S.S. and Abrahizadeh, H.A. 1998. Occurrence of a motile *Aeromonas* septicaemia in the imported ornamental fish, oscar *Astronotus ocellatus*: Isolation characterization and pathogenicity. J. Faculty Vet. Med. Univ. Tehran 53: 63-65.
- Ukwe, I. O. K. & Deekae, S. N. (2024). Phytochemical and Proximate Analysis of sweet potato (*Ipomea batatas*) leave aqueous extract and it's prophylactic effects on *Pseudomonas aeruginosa*. Infected *Clarias gariepinus*. Asian Journal of Aquatic Research, 26 (6): 76 – 87
- Ukwe, I. O. K., & Abu, O. M. G. (2021). Effect of dietary *Persea americana* on the organosomatic indices, diseases resistance, and liver histopathology of *Clarias gariepinus* exposed to *Klebsiella pneumoniae*. Asian Journal of Fisheries and Aquatic Research, 15(6), 148-156.
- Ukwe, I. O. K., & Gabriel, U. U. (2019). Herb and Herbal Supplements: Key to a Productive, Healthy, and Eco-Friendly Aquaculture Practice. *Delta Agriculturist*, 23, 123-130
- Ukwe, I.O.K. & Deekae, S.N. (2022). Phytochemical Assessment of *Persea americana* powdered leaves and its potency in protecting *Clarias gariepinus* against *Klebsiella pneumonia*. Asian Journal of Fisheries and Aquatic Research, 16(6): 1-9.
- Vivas, J., Carracedo, B., Riano, J., Razquin, B.E, Lopez-Fierro, P., Acosta, F., Naharro, G. and Villena, A.J. 2004. Behavior of an *Aeromonas hydrophila aroA* live vaccine in water microcosms. Appl. Environ. Microbiol. 70: 2702-2708.

**Disclaimer/Publisher's Note:** The statements, opinions and data contained in all publications are solely those of the individual author(s) and contributor(s) and not of the publisher and/or the editor(s). This publisher and/or the editor(s) disclaim responsibility for any injury to people or property resulting from any ideas, methods, instructions or products referred to in the content.

© Copyright (2025): Author(s). The licensee is the journal publisher. This is an Open Access article distributed under the terms of the Creative Commons Attribution License (<http://creativecommons.org/licenses/by/4.0>), which permits unrestricted use, distribution, and reproduction in any medium, provided the original work is properly cited.

*Peer-review history:*

The peer review history for this paper can be accessed here:  
<https://www.sdiarticle5.com/review-history/129546>